

УДК 616.126.421 + 616.132-007.64]-089.168

**A. Kalangos, S.M. Cherian, J. Jolou, J.-C. Pache, H. Muller,  
P.O. Myers, M. Cikirikcioglu**

Geneva University Hospitals, Switzerland

ОРИГІНАЛЬНІ  
ДОСЛІДЖЕННЯ

## Prophylactic aortic root replacement on Marfan patients undergoing mitral valve repair

Significant mitral regurgitation (MR) could be the first manifestation in Marfan syndrome, even before the onset of aortic dilatation or aortic regurgitation (AR).

**The aim** – to analyse the role of simultaneous prophylactic aortic root replacement in Marfan patients presenting primarily with MR, undergoing mitral valve repair.

**Materials and methods.** A 4-year (2007 to 2010) retrospective analysis of a single surgeon's experience included 13 Marfan patients (11 males, 2 females) aged between 12 to 60 years (mean 40.3). Pre-operative MR was grade III or more in all patients. Mechanisms of MR were anterior leaflet prolapse in 2 patients, and bi-leaflet prolapse in 11. All patients underwent mitral annuloplasty using a biodegradable intra-annular ring along with other mitral valve repair techniques. No patient had significant pre-operative AR, however, the aortic root diameter was greater than the physiologic range for their corresponding body surface area, hence, all patients underwent simultaneous prophylactic valve sparing aortic root replacement. Follow-up was complete in all patients, ranging from 1 to 4 years (mean 2.4).

**Results.** Post-operative MR at 6 months was grade 0 in 8 patients, and grade 1 in 5. No further progression was seen in any of the patients during the follow-up period. No progression in AR or aortic root complications were noted in any of the patients. There were no post-operative deaths.

**Conclusions.** Marfan patients with mitral regurgitation can be successfully repaired, with good short-term results. In patients with an aortic root diameter greater than their normal physiologic range, simultaneous prophylactic aortic root replacement is safe and effective in preventing complications associated with the disease.

**Key words:** Marfan's syndrome, mitral regurgitation, aortic aneurysm.

Marfan's syndrome is a connective tissue disorder [24] with a shortened life expectancy, due to its associated cardiovascular complications [27]. The progressive nature of this disease results in aortic regurgitation (AR), root dilatation, dissection, and eventual rupture [32]. If left untreated, death often occurs in the 3rd decade of life [22]. In addition to aortic disease, mitral valve dysfunction has been noted in upto 80 % of patients [13], in whom either mitral valve repair or replacement have been advocated.

The risk of aortic dissection correlates positively to the aortic root diameter [3], and it has been suggested that the risk of death of a Marfan patient from the initial aortic dissection is 40 %, and if the patient survives this initial episode, surgery carries an operative mortality of up to 20 %, with a 5-year survival of only 50 % [12, 28, 30]. Therefore, early surgery in Marfan patients, before the onset of acute aortic dissection, is proposed, with an overall hospital survival of 99 %, and good long-term survival [19, 29].

Kalangos Afksendiyos, MD, PhD, FECS, DSc  
Division of Cardiovascular Surgery University Hospital of Geneva  
Rue Gabrielle Perret-Gentil 4, Geneva, CH 1211, Switzerland  
Tel. (+41) 22-3727663, fax (+41) 22-3727634.  
E-mail : mustafa.cikirikcioglu@hcuge.ch

Стаття надійшла до редакції 26 лютого 2015 р.

However, the role of prophylactic aortic root replacement in Marfan patients with no AR or aortic root dilatation, is unclear.

The aim of study – to analyse the role of simultaneous prophylactic aortic root replacement in patients with Marfan syndrome presenting primarily with mitral dysfunction, who underwent mitral valve repair.

## Materials and methods

### Patient selection

A 4-year (January 2007 to December 2010) retrospective analysis of a single surgeon's experience consisted of 13 Marfan patients (11 males, 2 females), aged between 12 to 60 years (mean 40.3), with a body surface area (BSA) ranging from 1.7 to 2.4 (mean 2.14). The broad diagnosis of Marfan syndrome was based on the Ghent diagnostic criteria [7] with a positive family history, and the characteristic clinical findings of ocular, skeletal, and cardiovascular abnormalities 1. Patients with a «marfanoid» habitus, with no other «hard» signs, were excluded from the present study.

All patients underwent pre-operative clinical examination and investigations, including pre-, intra-, and post-operative 2-dimensional echocardiography according to standard diagnostic criteria [21]. The mechanism of mitral dysfunction was assessed, and the severity of MR was analysed and graded. Measurement of aortic root dimension, and assessment of AR were also undertaken during the same echocardiographic analysis.

The most common mechanism for MR was bi-leaflet prolapse, seen in 11 patients (84.6 %), and isolated anterior leaflet prolapse in 2 patients, with all patients presenting with symptomatic MR of grade III or more.

All 13 patients underwent elective mitral valve repair using a biodegradable intra-annular annuloplasty ring (Parvulus, Lonay, Switzerland). The characteristics of this ring, along with its implantation technique have been previously described [14]. In addition to ring annuloplasty, a total of 27 simultaneous repair procedures [4] were undertaken in these 13 patients, which included quadrangular resection, the use of artificial chordae, chordal shortening procedures, secondary chordal transfer, and anterior (or) posterior commissural closure (Table 1).

Although none of the Marfan patients in this series had significant pre-operative AR, the decision to undertake prophylactic replacement of the ascending aorta was based on the refined criteria as suggested by Roman [26], which takes into

**Table 1**  
**Simultaneous mitral valve repair procedures undertaken (total number 13 patients)**

Patients	Mitral valve repair procedures undertaken
6	Quadrangular resection
11	Artificial chordae
3	Chordal shortening
1	Secondary chordal transfer
6	Anterior (or) posterior commissural closure

account BSA in relation to the aortic root diameter at the level of the sinus of Valsalva. Since all 13 patients had an aortic root diameter greater than the physiologic range for their corresponding BSA, they all underwent simultaneous prophylactic aortic root replacement using the valve sparing David 1 operation [5], whereby the aortic root and the ascending aorta were replaced.

Once mitral annuloplasty was completed, the presence of any residual leak was assessed by saline testing. The adequacy of repair, MR, and AR were re-assessed by intra-operative trans-esophageal echocardiography after the patient was weaned off cardiopulmonary bypass, with valve performance and outcome analysis reported as per the guidelines of the American Association for Thoracic Surgery and the Society of Thoracic Surgeons [20]. The patients were managed post-operatively as routine, and all patients underwent trans-thoracic echocardiography on the 4th or 5th post-operative day, prior to discharge from hospital.

### Histological analysis

Histological examination of the aorta by hematoxylin-eosin, and Miller's stain (that specifically identifies elastic fibres) was undertaken in all 13 patients in order to assess the pathological alterations seen in Marfan syndrome. 10 specimens of normal aorta from non-Marfan patients undergoing other cardiac surgical operations (such as coronary artery bypass grafting) were used as controls, for comparative analysis.

### Follow-up

Follow-up was complete in all patients, ranging from 1 to 4 years (mean 2.4), in whom trans-thoracic echocardiography was performed prior to discharge from hospital, and annually thereafter. A total of 28 patient-years of follow-up were available for analysis, and 72 % of the patients were followed-up for a minimum of 2 years.

## Results

### Pre-operative status

The pre-operative symptom status was NYHA class III in 7, and class II in 6 patients, while pre-operative MR was grade IV in 6, and grade III in 7 patients. AR was grade 2 in 8 patients, grade 1 in 4, and grade 0 in 1 patient. The left ventricular ejection fraction (LVEF), left atrial (LA) diameter, left ventricular end-systolic dimension (LVESD), and left ventricular end-diastolic dimension (LVEDD) were noted. Pre-operative aortic root diameter ranged from 3.1 to 5 cm (mean  $3.82 \pm 0.50$ ), and the ascending aortic diameter ranged from 3 to 4.5 cm (mean  $3.41 \pm 0.44$ ).

### Post-operative status

All patients were in NYHA class I post-operatively. Post-operative MR at 6 months was grade 0 in 8, and grade I in 5. No further progression

was seen in any of the patients during the follow-up period, and none had mitral stenosis post-repair. Out of the 13 patients who underwent prophylactic aortic root replacement, 1 patient remained in grade 0 AR, while 12 patients had grade 1 AR. No progression in AR or aortic root complications were noted in any of the patients. A comparison between the pre-operative and post-operative status of the patients is tabulated in *Table 2*.

Mitral annular dilatation was present in all patients pre-operatively, for which, an intra-annular biodegradable annuloplasty ring was used in all 13 patients in order to provide annular support, and prevent recurrent annular dilatation. The annuloplasty ring size ranged from 26 to 36, with the mean ring size being 34.

All 13 patients had an aortic root diameter greater than the normal physiologic range for their corresponding BSA, as suggested by Roman's graph (*Fig. 1*), hence, all underwent simultaneous

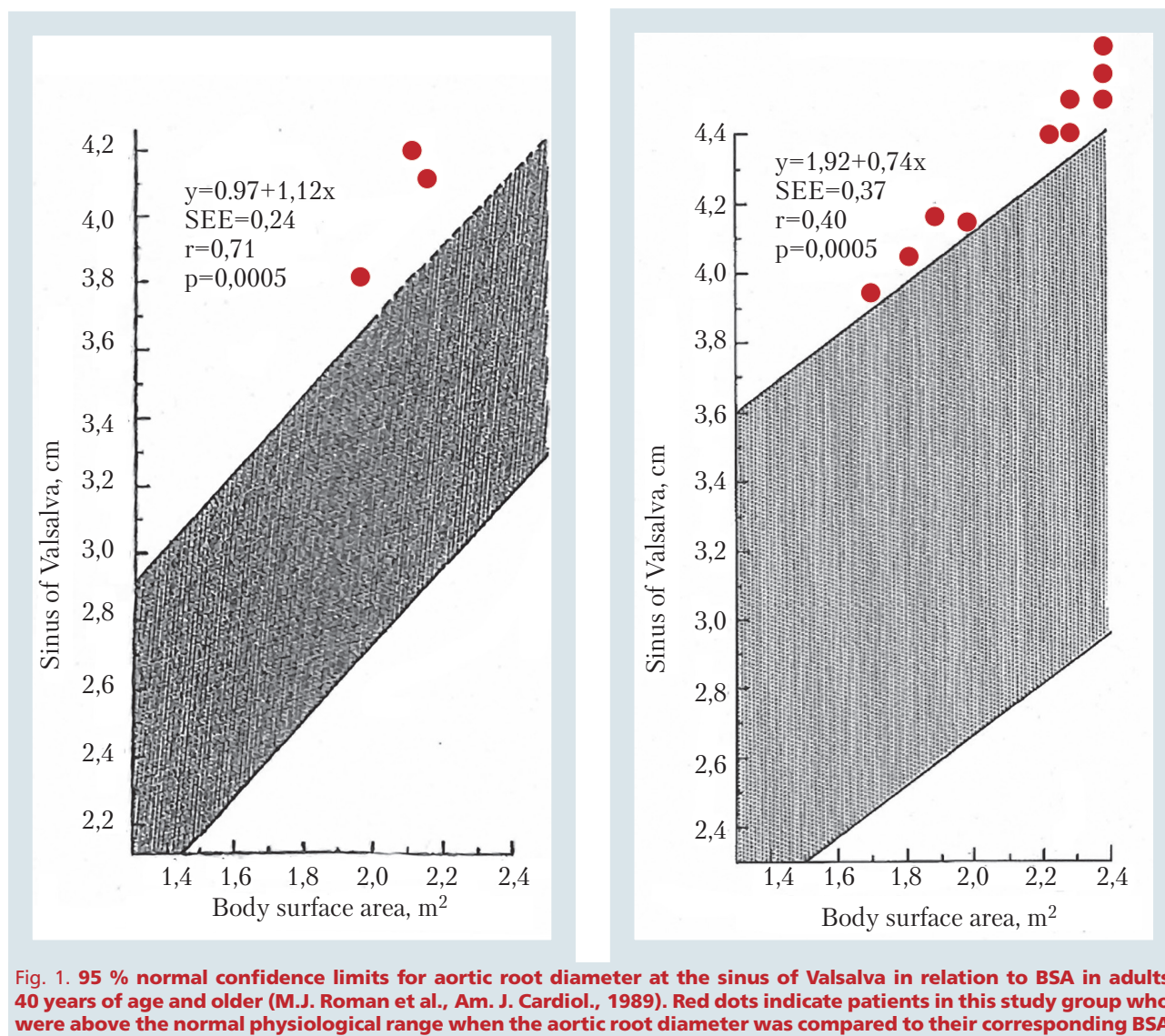


Fig. 1. 95 % normal confidence limits for aortic root diameter at the sinus of Valsalva in relation to BSA in adults 40 years of age and older (M.J. Roman et al., Am. J. Cardiol., 1989). Red dots indicate patients in this study group who were above the normal physiological range when the aortic root diameter was compared to their corresponding BSA



Table 2

**Comparison of pre-operative and post-operative parameters**

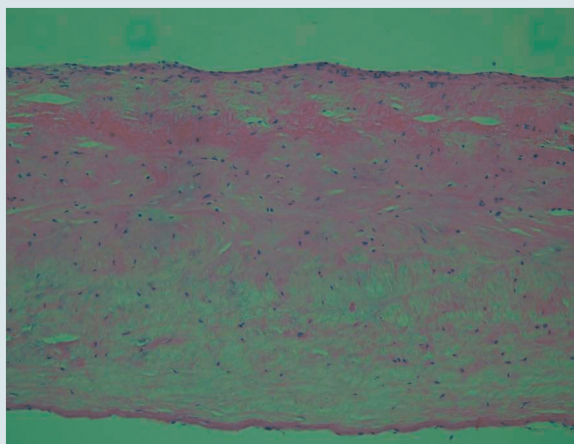
Parameters	Pre-operative	Post-operative
LVEF, %	55–75 (mean 56.9)	55–65 (mean 55.5)
LA diameter, cms	5.0–6.9 (mean 6.1)	3.7–5.3 (mean 4.46)
LVESD, cms	3.1–6.0 (mean 5.05)	3.1–4.2 (mean 3.72)
LVEDD, cms	5.6–7.2 (mean 6.55)	4.3–5.6 (mean 5.07)
Aortic root diameter, cms	3.1–5.0 (mean 3.82)	2.2–4.7 (mean 3.42)
Ascending aortic diameter, cms	3.0–4.5 (mean 3.41)	2.0–3.4 (mean 2.93)

LVEF – left ventricular ejection fraction; LA – left atrium; LVESD – left ventricular end systolic diameter; LVEDD – left ventricular end diastolic diameter.

prophylactic valve-sparing aortic root replacement employing the David technique [5]. The size of the Dacron tube used ranged from 26 to 32 mm, with the mean tube size being 30 mm.

The cardio-pulmonary bypass (CPB) time ranged from 72 to 246 mins (mean  $127.0 \pm 45.8$ ), and the aortic cross-clamp (ACC) time ranged from 52 to 186 mins (mean  $93.0 \pm 34.7$ ).

The in-hospital mortality was 0 in this series, and no re-repairs of the mitral or aortic valves were necessary in the post-operative period for any of the patients. No major post-operative complications such as stroke, acute myocardial ischemia/infarction, nor conduction defects occurred.



**Fig. 2. Hematoxylin and eosin stain of control aortic wall showing normal anatomy of tunica intima, media and adventitia, with normal arrangement of elastic and collagen fibres. Magnification  $\times 25$**

## Histological observations

When compared to the normal controls (*Fig. 2*), we observed a fragmentation and a disorganisation of the elastic and collagen fibers in the aortic wall of Marfan patients. On higher magnification, it was noted that the elastic and collagen fibers in the tunica media and tunica adventitia were either partially or completely fragmented, giving rise to an obvious «line of weakness» within the tunica media. This was observed with the non-specific hematoxylin stain. This could be the result of biochemical alterations of the collagen structures that may bind to the hematoxylin dye. These chemical and structural modifications may lead to a decreased resistance to the shear forces that act within the aortic wall during systole and diastole. This «line of weakness» may thus progress with time and ultimately form the «plane of dissection» in the future.

This «line of weakness» abnormality was further confirmed by Miller's stain which demonstrated elastic fiber fragmentation, disorganization in collagen bundle arrangement, associated with myxomatous changes (*Fig. 3, 4*).

At the last follow-up, all 13 patients were free from any valve-related complications (regurgitation, stenosis, or endocarditis), with all patients in NYHA class I. None of these patients required long-term anticoagulation with warfarin. No thromboembolic events and no anticoagulant related hemorrhage were observed.

## Discussion

### Significance of this study

To the best of our knowledge, literature search suggests that this series represents one of the largest number of Marfan patients who have undergone prophylactic aortic root replacement using the guidelines based on correlating the aortic root diameter to BSA [1].

This study clearly demonstrates the rationale for prophylactic aortic root replacement in Marfan patients, based on the histological evidence of the «line of weakness» represented by the fragmentation/disruption of elastic and collagen fibres within the aortic wall.

Literature search also suggests that this study may represent one of the largest series of Marfan patients who have undergone simultaneous aortic root replacement and mitral valve repair procedures.

Mitral dysfunction in Marfan is known to precede aortic involvement in some cases, with even mild valvular incompetence gradually progressing in severity in almost 50 % of cases [10, 13, 25]. Treatment has now evolved to «preventing» the complications associated with aortic dilatation, rather

than just «treating» them after they have occurred. Although it is undisputed that Marfan patients presenting with significant MR would benefit from mitral valve repair, it is unclear whether it is prudent to undertake simultaneous prophylactic aortic root replacement in these patients. The current study aimed at providing an answer to this dilemma.

This study comprised of 13 Marfan patients, in whom mitral valve dysfunction, without aortic disease, was the primary presentation. Mitral repair was achieved in all patients, regardless of the mechanism of dysfunction, by using a combination of different repair techniques along with an intra-annular biodegradable annuloplasty ring. This study suggests that mitral valve repair is a safe procedure in Marfan syndrome, as evidenced by zero hospital mortality. Follow-up was complete in 100 % of patients, and ranged from 1 to 4 years, with a mean follow-up period of 2.4 years. Approximately 72 % of the patients were followed-up for a minimum of 2 years, indicating an acceptable early follow-up period in the vast majority of patients in this series.

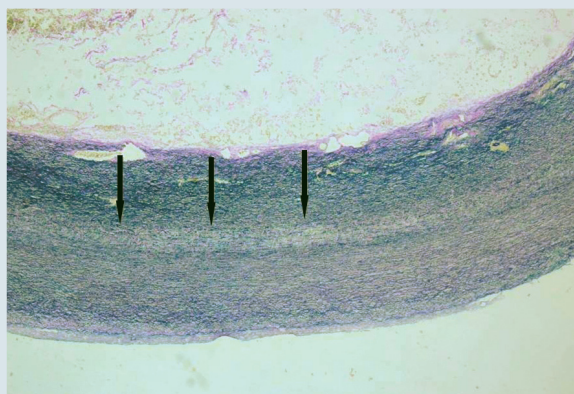
Although prophylactic aortic root replacement has been suggested, there is continued debate on the aortic diameter at which surgery should be undertaken. The Dutch guidelines [33] specifies an aortic root diameter of  $> 5.5$  cm in non-Marfan patients, an aortic root diameter of  $> 5$  cm in patients with a family history of aortic dissection,  $> 4.5$  cm in Marfan patients, or an aortic root dilatation of  $> 0.2$  cm/year. However, previous studies have clearly proven that aortic dissection can occur even below these «guideline values» [2, 18].

Since the aortic root diameter (at the level of the sinus of Valsalva) is dependent on BSA [17, 26], instead of using the above mentioned fixed values, we applied this principle to guide our decision

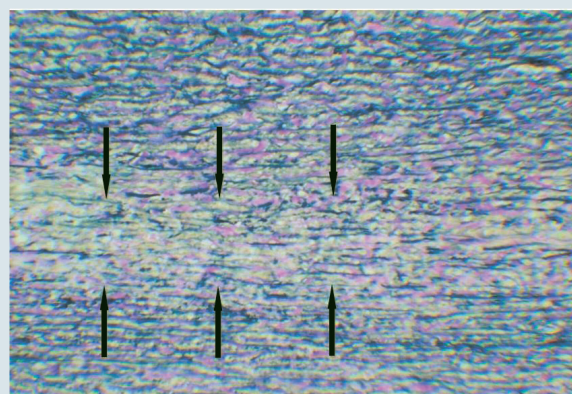
for prophylactic aortic root replacement in all the 13 patients. We used the «maximum» predicted aortic root diameter (ie the upper limit of normal), rather than the «mean» predicted aortic root diameter in order to prevent these patients from being subjected to surgical intervention «too early». This approach is supported by earlier studies on thoracic aneurysms which demonstrated that «relative» aortic diameter (corrected for BSA) was more important than the «absolute» aortic diameter in predicting aortic rupture [6].

In order to prevent further annular dilatation in Marfan syndrome, it is important to stabilize the annulus while performing valve-sparing procedures [16]. Hence, the valve-sparing aortic root replacement technique as proposed by David was chosen for all our patients, since subsequent annular dilatation is prevented as the entire aortic valve is secured inside the un-yielding tubular vascular graft [5]. Furthermore, replacement of the ascending aorta overcomes the potential complications involving future dilatation of the sino-tubular junction. Additionally, in this series, the David procedure was undertaken on an elective basis, providing better long-term results when compared to a Bentall procedure performed on an emergency basis.

When applying the Laplace's law, aortic wall tension is dependent only on pressure, radius and wall thickness, whereby it may appear that the concept of prophylactic aortic root replacement is too «radical» and not warranted, since it could be argued that people with large BSA may also have a thick aortic wall. However, it must be remembered that although Marfan patients may have a «normal looking aortic wall thickness» and a «normal looking anatomic diameter», the collagen dysfunction secondary to fibrillin mutation, renders



**Fig. 3. Miller's stain showing the same area (as analysed in Figure 1 by hematoxylin and eosin stain) within the aortic wall of Marfan patients, black arrows demonstrating the «line of weakness» due to fragmentation and disorganization of elastic and collagen fibres within the tunica media. Magnification  $\times 25$**



**Fig. 4. Miller's stain, black arrows denoting the boundaries of the «line of weakness» due to fragmentation and disorganization of elastic and collagen fibres within the tunica media in Marfan syndrome. Magnification  $\times 100$**

their aorta prone for aortic dissection in the long-term as suggested by the histological findings.

### **Rationale for prophylactic aortic root replacement**

In concurrence with previous pathological studies [8, 9], histological analysis of the «apparently normal aorta» obtained during prophylactic aortic root replacement in our patients, clearly demonstrated a partial or complete fragmentation of the collagen and elastic fibres, along with myxoid infiltration in all 13 Marfan patients.

Fibrillin-1 monomers form extracellular macroaggregates called microfibrils that are vital for the integrity of elastic and non-elastic tissues [23], and serve as an «anchoring scaffold» for the elastin network. Mutations of fibrillin-1 in Marfan syndrome, hence leads to fragmentation of collagen and elastin fibers eventually causing tissue disruption.

This study clearly demonstrated a «line of weakness» characterised by the disruption and absence of elastic and collagen fibres within the tunica media. This «line of weakness» may represent the plane through which aortic dissection is most likely to occur at a later date, rendering adequate proof to our hypothesis that Marfan patients may benefit from prophylactic aortic root replacement.

Furthermore, mortality is as high as 20 % in patients undergoing surgical correction of acute Type A aortic dissections [31], while mortality is as low as 2 % for those undergoing elective aortic root replacement surgery [11, 18]. Hence, these inferences give additional support to our proposition for performing prophylactic, rather than to perform emergency surgery on Marfan patients after an episode of aortic dissection has occurred.

Moreover, cardiac re-operations are technically more demanding than primary surgical interventions, and this may be especially important in the case of Marfan patients. Since the patients in this series presented with significant mitral dysfunction that warranted surgical intervention, it seems justifiable to perform both the mitral valve repair, as well as the prophylactic aortic root replacement (in those patients who fulfilled the Roman's criteria) during the same procedure.

The results of this study suggest that the protocol of correlating the aortic root diameter to the BSA is safe and effective during early follow-up, since there were no mortalities, and no aortic root complications post-operatively. Furthermore, with preservation of the aortic valve using the valve sparing aortic root replacement procedure, the role for mitral valve repair, rather than mitral valve replacement, is more practical, thereby completely

avoiding the need for long-term anticoagulation, and its associated complications of bleeding and thromboembolism.

In addition to performing surgical prophylaxis for aortic wall complications, medical prophylaxis is also vital. For this reason, all patients in this study received antihypertensive therapy with a beta-blocker [15], unless contra-indicated, in which case, alternative treatment consisted of an angiotensin-converting enzyme (ACE) inhibitor. However, it is vital that all Marfan patients are made aware of the progressive nature of their disease, and the risk of subsequent re-operations in the future.

### **Limitations of this study**

Patient randomization was impossible due to the retrospective design. It is difficult to draw significant statistical conclusions due to the relatively small patient cohort with few adverse outcomes. Although all patients fulfilled the «Ghent diagnostic criteria» for Marfan syndrome, due to financial constraints, not all patients underwent genetic testing for re-confirmation.

Patients who underwent repair in the recent years were monitored for shorter periods when compared to patients who underwent repair earlier in the series, stressing the need for longer follow-up of these new patients in order to better delineate the efficacy of repair. Periodic imaging of the entire aorta is essential, however, this has not been performed in all our patients. Furthermore, all direct relatives should be assessed for Marfan syndrome, which was only partially undertaken in this study.

### **Conclusions**

Our observations suggest that simultaneous prophylactic aortic root replacement at the time of mitral valve repair is safe and effective in the short-term in patients with Marfan syndrome. Since the cardiovascular complications in Marfan syndrome involving the aorta and mitral valve are potentially fatal, early surgical intervention may improve the outlook. However, a larger series of patients, with long-term follow-up is required to make firm conclusions on the most appropriate individually tailored treatment in Marfan syndrome.

**Author contributions:** Cherian S.M. – concept and design of the study, drafting of the article; Jolou J. – data collection, data analysis and interpretation; Pache J.-C. – pathological analysis, critical revision of manuscript; Muller H. – data analysis, critical revision of manuscript; Cikiri-kcioglu M. – critical revision of manuscript and approval of article; Kalangos A. – critical revision of manuscript and approval of article.



## References

1. Aalberts J.J., Waterbolk T.W., van Tintelen J.P. et al. Prophylactic aortic root surgery in patients with Marfan syndrome: 10 years' experience with a protocol based on body surface area // *Eur. J. Cardiothorac. Surg.*– 2008.– Vol. 34.– P. 589–594.
2. Alexiou C., Langley S.M., Charlesworth P. et al. Aortic root replacement in patients with Marfan's syndrome: the Southampton experience // *Ann. Thorac. Surg.*– 2001.– Vol. 72.– P. 1502–1507.
3. Cañadas V., Vilacosta I., Bruna I., Fuster V. // *Nat Rev. Cardiol.*– 2010.– Vol. 7.– P. 256–265 (266–276).
4. Carpentier A. Cardiac valve surgery – the «French correction» // *J. Thorac. Cardiovasc. Surg.*– 1983.– Vol. 86.– P. 323–337.
5. David T.E., Armstrong S., Maganti M. et al. Long-term results of aortic valve-sparing operations in patients with Marfan syndrome // *J. Thorac. Cardiovasc. Surg.*– 2009.– Vol. 138.– P. 859–864.
6. Davies R.R., Gallo A., Coady M.A. et al. Novel measurement of relative aortic size predicts rupture of thoracic aortic aneurysms // *Ann. Thorac. Surg.*– 2006.– Vol. 81.– P. 169–177.
7. De Paepe A., Devereux R.B., Dietz H.C. et al. Revised diagnostic criteria for the Marfan syndrome // *Am. J. Med. Genet.*– 1996.– Vol. 24.– P. 417–426.
8. Fleischer K.J., Nousari H.C., Anhalt G.J. et al. Immuno-histochemical abnormalities of fibrillin in cardiovascular tissues in Marfan's syndrome // *Ann. Thorac. Surg.*– 1997.– Vol. 63.– P. 1012–1017.
9. Fornes P., Heudes D., Fuzellier J.F. et al. Correlation between clinical and histologic patterns of degenerative mitral valve insufficiency: a histomorphometric study of 130 excised segments // *Cardiovasc. Pathol.*– 1999.– Vol. 8.– P. 81–92.
10. Gillinov A.M., Hulyalkar A., Cameron D.E. et al. Mitral valve operation in patients with the Marfan syndrome // *J. Thorac. Cardiovasc. Surg.*– 1994.– Vol. 107.– P. 724–731.
11. Gott V.L., Cameron D.E., Alejo D.E. et al. Aortic root replacement in 271 Marfan patients: a 24-year experience // *Ann. Thorac. Surg.*– 2002.– Vol. 73.– P. 438–443.
12. Gott V.L., Greene P.S., Alejo D.E. et al. Replacement of the aortic root in patients with Marfan's syndrome // *New Engl. J. Med.*– 1999.– Vol. 29.– P. 1307–1313.
13. Hirata K., Triposkiadis F., Sparks E. et al. The Marfan syndrome: cardiovascular physical findings and diagnostic correlates // *Am. Heart J.*– 1992.– Vol. 123.– P. 743–752.
14. Kalangos A., Sierra J., Vala D. et al. Annuloplasty for valve repair with a new biodegradable ring: an experimental study // *J. Heart Valve Dis.*– 2006.– Vol. 15.– P. 783–790.
15. Keane M.G., Pyritz R.E. Medical management of Marfan syndrome // *Circulation.*– 2008.– Vol. 27.– P. 2802–2813.
16. Konstantinov I.E., Jalali H. Total chordal augmentation in a child with Marfan syndrome and severe mitral insufficiency // *Tex Heart Inst. J.*– 2007.– Vol. 34.– P. 423–424.
17. Legget M.E., Unger T.A., O'Sullivan C.K. et al. Aortic root complications in Marfan's syndrome: identification of a lower risk group // *Heart.*– 1996.– Vol. 75.– P. 389–395.
18. Meijboom L.J., Timmermans J., Zwinderman A.H. et al. Aortic root growth in men and women with the Marfan's syndrome // *Am. J. Cardiol.*– 2005.– Vol. 15.– P. 1441–1444.
19. Miller D.C. Valve-sparing aortic root replacement in patients with the Marfan syndrome // *J. Thorac. Cardiovasc. Surg.*– 2003.– Vol. 125.– P. 773–778.
20. Miller D.C., Weisel R.D. Guidelines for reporting morbidity and mortality after cardiac valvular operations // *Ann. Thorac. Surg.*– 1996.– Vol. 62.– P. 932–935.
21. Morganroth J., Jones R.H., Chen C.C. et al. Two-dimensional echocardiography in mitral, aortic and tricuspid valve prolapsed // *Am. J. Cardiol.*– 1986.– Vol. 46.– P. 1164.
22. Murdoch J.L., Walker B.A., Halpern B.L. et al. Life expectancy and causes of death in the Marfan syndrome // *New Engl. J. Med.*– 1972.– Vol. 13.– P. 804–808.
23. Pereira L., Andrikopoulos K., Tian J. et al. Targetting of the gene encoding fibrillin-1 recapitulates the vascular aspect of Marfan syndrome // *Nat. Genet.*– 1997.– Vol. 17.– P. 218–222.
24. Pyritz R.E., McKusick V.A. The Marfan syndrome: diagnosis and management // *New Engl. J. Med.*– 1979.– Vol. 5.– P. 772–777.
25. Pyritz R.E., Wappel M.A. Mitral valve dysfunction in the Marfan syndrome. Clinical and echocardiographic study of prevalence and natural history // *Am. J. Med.*– 1983.– Vol. 74.– P. 797–807.
26. Roman M.J., Devereux R.B., Kramer-Fox R., Spitzer M.C. Comparison of cardiovascular and skeletal features of primary mitral valve prolapse and Marfan syndrome // *Am. J. Cardiol.*– 1989.– Vol. 1.– P. 317–321.
27. Silverman N.H., Gerlis L.M., Horowitz E.S. et al. Pathologic elucidation of the echocardiographic features of Ebstein's malformation of the morphologically tricuspid valve in discordant atrioventricular connections // *Am. J. Cardiol.*– 1995.– Vol. 15.– P. 1277–1283.
28. Smith J.A., Fann J.I., Miller D.C. et al. Surgical management of aortic dissection in patients with the Marfan syndrome // *Circulation.*– 1994.– Vol. 90.– P. 11235–242.
29. Svensson L.G., Blackstone E.H., Feng J. et al. Are Marfan syndrome and marfanoid patients distinguishable on long-term follow-up? // *Ann. Thorac. Surg.*– 2007.– Vol. 83.– P. 1067–1074.
30. Svensson L.G., Crawford E.S., Coselli J.S. et al. Impact of cardiovascular operation on survival in the Marfan patient // *Circulation.*– 1989.– Vol. 80.– P. 1233–242.
31. Trimarchi S., Nienaber C.A., Rampoldi V. et al. International Registry of Acute Aortic Dissection Investigators: Contemporary results of surgery in acute type A aortic dissection: The International Registry of Acute Aortic Dissection experience // *J. Thorac. Cardiovasc. Surg.*– 2005.– Vol. 129.– P. 112–122.
32. Van Karnebeek C.D., Naeff M.S., Mulder B.J. et al. Natural history of cardiovascular manifestations in Marfan syndrome // *Arch. Dis. Child.*– 2001.– Vol. 84.– P. 129–137.
33. Working group «Congenitale cardiologie bij volwassenen» of the Dutch Society of Cardiology. Adult congenital heart disease in the Netherlands: Guidelines 2000. The Hague: The Netherlands Heart Foundation.– 2000.

**A. Kalangos, S.M. Cherian, J. Jolou, J.-C. Pache, H. Muller, P.O. Myers, M. Cikirikcioglu**

Університетський госпіталь Женеви, Швейцарія

## Профілактична заміна кореня аорти в пацієнтів із синдромом Марфана при виконанні пластики мітрального клапана

Значна мітральна регургітація (МР) може бути першим виявом синдрому Марфана, навіть до настання дилатації аорти або аортальної регургітації (АР).

**Мета роботи** – провести аналіз симульованої профілактичної заміни кореня аорти в пацієнтів із синдромом Марфана, що надійшли з діагнозом МР для виконання пластики мітрального клапана.

**Матеріали і методи.** Проведено ретроспективний аналіз чотирирічного досвіду (2007–2010 рр.) одного хірурга. У дослідження залучено 13 хворих із синдромом Марфана (11 чоловіків, 2 жінки) віком 12–60 років (у

середньому 40,3 року). У всіх пацієнтів перед операційним лікуванням була недостатність мітрального клапана 3-го ступеня і більше. В основі механізму МР у двох хворих був пролапс передньої стулки, і 11 пацієнтів мали пролапс обох стулок. Усім хворим виконали мітральну анулопластику з використанням біодеградувального інтраанулярного кільця в поєднанні з іншими техніками пластики мітрального клапана. Перед операцією жоден пацієнт не мав значної АР, проте діаметр кореня аорти перевищував фізіологічний діапазон для відповідної площі поверхні тіла, отже, всі пацієнти пройшли одночасно профілактичну клапанозберігальну заміну кореня аорти з подальшим спостереженням від 1 до 4 років (у середньому 2,4 року).

**Результати.** Через 6 міс після операції недостатність мітрального клапана 0 ступеня була у 8 пацієнтів і 1-го ступеня – у 5 пацієнтів. За період спостереження в жодному з випадків не відзначено прогресування мітральної недостатності або АР. Не було ускладнень, пов'язаних із коренем аорти. Післяопераційної летальності за весь період спостереження не реєстрували.

**Висновки.** У пацієнтів із синдромом Марфана і МР пластика мітрального клапана може виконуватися успішно з добрим найближчим результатом. У пацієнтів із діаметром кореня аорти, що перевищує його фізіологічний діапазон, одночасна профілактична заміна кореня аорти безпечна й ефективна для запобігання ускладнень, пов'язаних із захворюванням.

**Ключові слова:** синдром Марфана, недостатність мітрального клапана, аневризма аорти.

**A. Kalangos, S.M. Cherian, J. Jolou, J.-C. Pache, H. Muller, P.O. Myers, M. Cikirikcioglu**

Университетский госпиталь Женевы, Швейцария

### Профилактическая замена корня аорты у пациентов с синдромом Марфана при выполнении пластики митрального клапана

Значительная митральная регургитация (МР) может быть первым проявлением синдрома Марфана, даже до наступления дилатации аорты или аортальной регургитации (АР).

**Цель работы** – провести анализ симультантной профилактической замены корня аорты у пациентов с синдромом Марфана, поступивших с диагнозом МР для выполнения пластики митрального клапана.

**Материалы и методы.** Проведен ретроспективный анализ четырехлетнего опыта (2007 – 2010 гг.) одного хирурга. В исследование включено 13 больных с синдромом Марфана (11 мужчин, 2 женщины) в возрасте 12–60 лет (в среднем 40,3 года). У всех пациентов перед операционным лечением была недостаточность митрального клапана 3-й степени и более. В основе механизма МР у двух больных был пролапс передней створки, и 11 пациентов имели пролапс обеих створок. Всем больным выполнена митральная анулопластика с использованием биodeградирующего интраанулярного кольца в сочетании с другими техниками пластики митрального клапана. Перед операцией ни один пациент не имел значительной АР, однако диаметр корня аорты превышал физиологический диапазон для соответствующей площади поверхности тела, следовательно, все пациенты прошли одновременно профилактическую клапансохраняющую замену корня аорты с последующим наблюдением от 1 года до 4 лет (в среднем 2,4 года).

**Результаты.** Через 6 мес после операции недостаточность митрального клапана 0 степени была у 8 пациентов, и 1-й степени – у 5 пациентов. За период наблюдения ни в одном из случаев не отмечено прогрессирования митральной недостаточности или АР. Не было осложнений, связанных с корнем аорты. Послеоперационная летальность за весь период наблюдения отсутствовала.

**Выводы.** У пациентов с синдромом Марфана и МР пластика митрального клапана может выполняться успешно с хорошим ближайшим результатом. У пациентов с диаметром корня аорты, превышающим его физиологический диапазон, одновременная профилактическая замена корня аорты является безопасной и эффективной для предотвращения осложнений, связанных с заболеванием.

**Ключевые слова:** синдром Марфана, недостаточность митрального клапана, аневризма аорты.